

## **Microsurgical Limb Reconstruction Utilizing Truelok TL External Fixator: A Case Report**

**E. Rodriguez-Collazo, J. Huey**

Presence Saint Joseph Hospital – Chicago, USA

---

Coverage of lower extremity wounds, especially those in the distal leg, present challenges to the reconstructive surgeon. The present case illustrates a surgical technique utilizing a distally based reverse soleus muscle flap for coverage of an anterior leg wound deficit with exposed bone. The wound failed conservative wound care and was at risk of a below the knee amputation. The wound was first debrided to healthy bleeding tissue. The Truelok TL External Fixator was then applied for stabilization of the muscle flap. The medial portion of the soleus muscle was dissected with care to preserve its vascular supply and transposed to cover the wound defect. This was followed by utilization of the Integra Bi-Layer Matrix to control the vapor loss of the wound, act as a bacterial barrier, and provide a scaffold for cellular invasion and capillary growth. A wound VAC was applied to promote granular tissue formation. Following post-operative wound care, a split-thickness skin graft was later applied. The limb was salvaged and wound closure was achieved within three months. The patient began ambulating in a patella tendon bearing orthosis within four months. The reserve soleus muscle flap provides a viable option for ankle wound and anterior leg coverage, especially in medically frail patients. Due to a high degree of versatility, reliability, minimal donor site morbidity, less operating time, low cost and good functional gain; this procedure is highly suitable for the treatment of complex middle and lower leg defects. It should be considered in the reconstruction of soft tissue defects about the ankle, especially when the surgeon has exhausted all other conservative and surgical options.

**Keywords:** Soleus, Muscle Flap, Limb Salvage, Advanced Orthoplastic Technique, External Fixator, Wound VAC, Integra, Truelok, Split-thickness Skin Graft, Anterior Leg Wound, Ankle Wound Coverage

---

### INTRODUCTION

Soft-tissue defects and complex wounds in the foot and leg represent a great challenge for the reconstructive surgeon. In the ankle region, the paucity of muscle and thin subcutaneous tissues make the area prone for wound break down. This loss of soft tissue coverage poses threats of amputation to exposed bony structures [1]. Conservative approaches to this problem include localized wound care, amniotic products, fiberglass casting, amniotic grafts, and negative pressure therapies. If these methods fail, the surgeon must decide if limb salvage is the optimal choice for the patient. If so, the surgeon must be aggressive with their treatment plan [2]. In plastic surgery, wound coverage options include free flap transfers and muscle flap transfers. These are useful especially in trauma, when primary closure cannot be achieved and a large, at risk defect is present [3–4].

The transposition of the soleus muscle as a flap has been described by many authors as a viable option in properly selected patients for coverage of wounds around the ankle [5–13]. It poses lower donor site morbidity, less risk in medically frail patients, and is not as technically demanding as other flap techniques. This

simple procedure enables the soleus muscle to be advanced distally, extending its application for coverage of the distal lower leg. The soleus muscle is a type II muscle flap (14) and is an optimal choice for coverage of large wound defects of the anterior leg. The soleus has a dominant vascular pedicle and minor distal vascular pedicles. It can be transposed to the anterior leg & ankle [15], the plantar heel, medial arch, and transmetatarsal amputation sites. Additionally, it allows for easy dissection, can be modified to create more length, and is a large muscle belly that allows for coverage of larger wounds.

In this paper we present a patient with an anterior leg wound measuring 10.0 × 5.0 × 1.0-cm deep wound with exposed bone, at risk for amputation, that had failed conservative wound care therapy. Utilizing a distally based reverse soleus muscle flap, Integra Bilayer graft, partial thickness skin graft, wound VAC, and Ilizarov external fixation, this wound was able to be closed in three months and the limb was salvaged. We outline a step-by-step approach to the soleus muscle flap and proper care of the flap to maximize suitability.

## CASE REPORT

The patient is a 62 year old male who was evaluated for a surgical wound of the anterior distal left leg status post removal of infected hardware. Four years prior, patient had undergone surgical reconstruction of a rigid cavovarus foot. Hardware subsequently became infected from a plantar heel wound and the hardware was removed (**Fig. 1**). Primary closure could not be completed and a vessel loop delayed closure was performed. He was treated with IV antibiotics and local wound care, but wound got worse. A reverse soleus muscle flap for coverage of exposed bone and wound defect was then planned. His past medical history was significant for uncontrolled type 2 diabetes, charcot arthropathy, and extensive history of lower leg wounds with fasciotomy due to episode of necrotizing fasciitis, osteomyelitis of the foot treated with IV antibiotics.

The physical examination demonstrated palpable dorsalis pedis and posterior tibial artery pulses. Arterial doppler ultrasound showed biphasic wave forms of the dorsalis pedis, posterior tibial, and peroneal arteries. Muscle strength was weakened in all muscular compartments of the lower leg. His skin was thin and warm to the touch. The patient was neurosensory compromised to the level of the lower leg, unable to discern vibratory, proprioception, or 5.07 Semmes-Weinstein Monofilament. A chronic-appearing, full-thickness, anterior distal leg wound, measuring 10.0×5.0×1.0-cm deep with mixed eschar, fibrinous tissue, and unhealthy granular tissue was present (**Fig. 2**). MRI was concerning for possible underlying infected hardware.

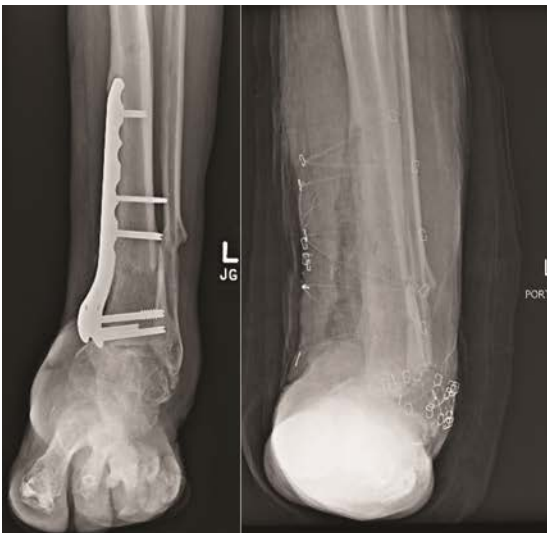#### Surgical Technique

A staged surgical approach was planned, consisting of debridement, flap coverage of the wound with exter-

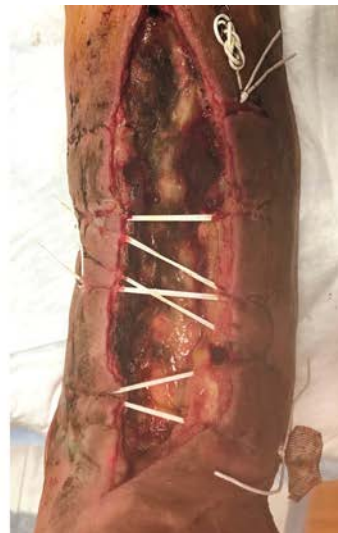nal fixation, and delayed skin grafting of the muscle flap followed by negative pressure therapy.

First, the surgical wound was debrided of all non-viable tissue to healthy bleeding base. Because of his history of skin breakdown and to allow nursing care and mobilization of the patient while maintaining stability of the reconstructive site, an external fixator was constructed and applied to the limb. The Orthofix TrueLok Trauma Frame was formed using one full ring, one foot plate, and adjustable struts (**Fig. 3**). The external fixator was secured to the patient's extremity by two half pins inserted in the leg and one placed in the midfoot. Corresponding fixation pins were inserted into the leg and foot and tension appropriately. External fixation was utilized to avoid traction/disruption of the proximal dominant pedicle and the distal minor pedicles [14], thus preventing interruption of the vascular viability of the muscle flap.

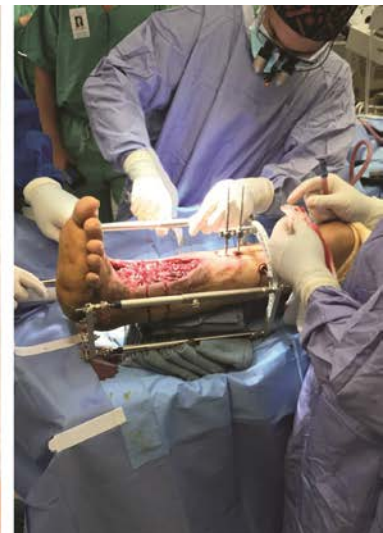Next, a longitudinal incision was performed extending from the anterior leg wound to the medial proximal leg. Incision was deepened to the level of the fascia with care being taken to identify and retract all vital neurovascular structures. Extensive fibrosis of underlying tissue was noted. All bleeders were cauterized and tied as necessary. The surgical site was flushed with copious amounts of hydrogen peroxide to assist with hemostasis. The fascia of the medial soleus muscle was identified and transected. The muscle was identified and removed from its origin in the proximal leg. After ensuring adequate bleeding, the muscle belly was transposed to the distal leg deficit and sutured in place with absorbable suture on a taper needle, adequately covering the wound defect (**Fig. 4**).



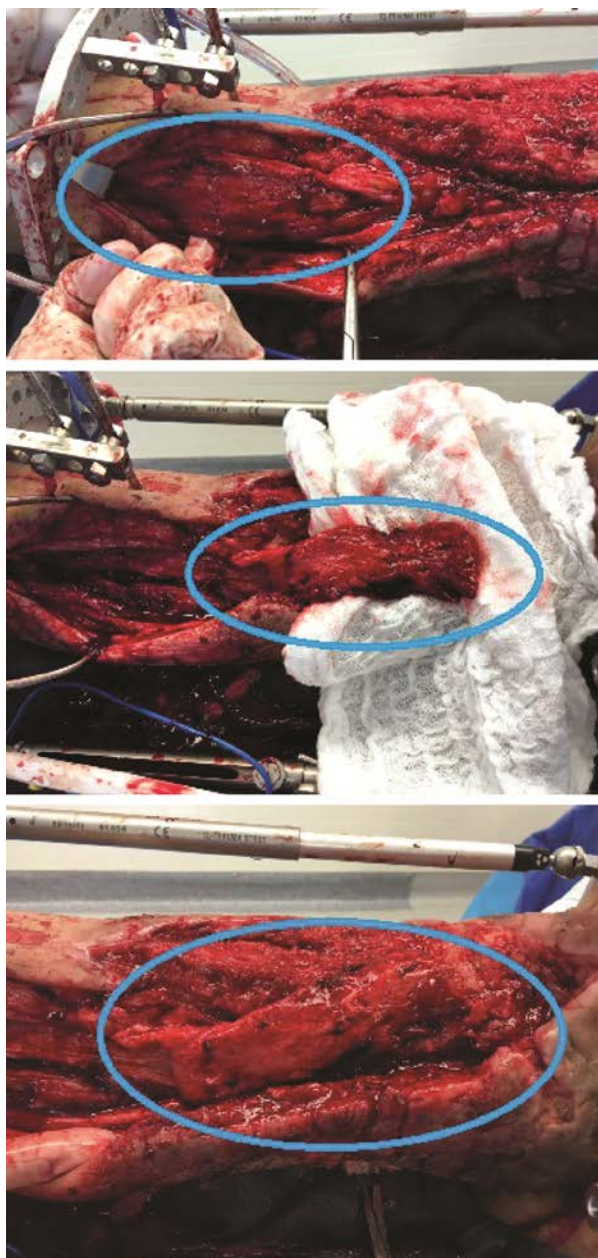**Fig. 1** Patient has retained hardware from surgical correction of rigid cavovarus foot deformity. The hardware subsequently became infected years later after the patient developed a wound that tracked to the ankle. The hardware was surgically removed



**Fig. 2** Post-operative wound after removal of hardware at distal leg. After wound dehiscence, conservative therapies failed to reduce the size of the wound. The patient was left with a large, full thickness wound measuring 10.0 × 5.0 × 1.0-cm deep with mixed eschar, fibrinous tissue, and unhealthy granular tissue

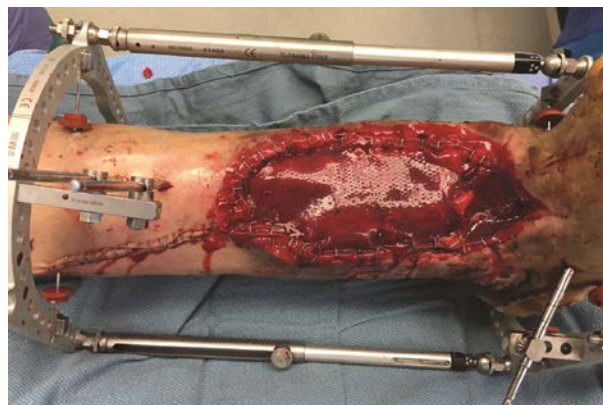

**Fig. 3** After debridement of the surgical wound, an Orthofix TrueLok Trauma Frame was utilized to immobilize the surgical site to prevent traction to the arterial perforators to the soleus muscle; maintaining vascular viability of the muscle flap. One full ring, one foot plate, and adjustable struts were used



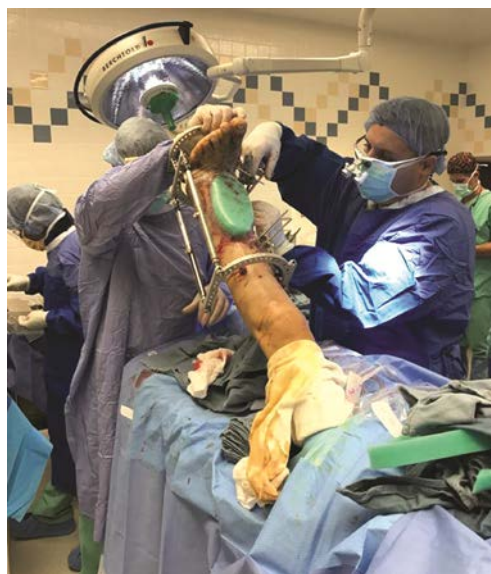**Fig. 4** The medial soleus muscle was identified and removed from its origin at the proximal leg and transposed to the distal leg deficit

The wound was covered with an Integra Bi-layer Matrix Wound Dressing and fixed accordingly to manufacturers specifications (**Fig. 5**). The Integra Bi-Layer Matrix is comprised of a porous matrix of cross-linked bovine tendon collagen and glycosaminoglycan and a semi-permeable polysiloxane (silicone) layer. This graft was used to 1) provide a semi-permeable membrane to control vapor loss and acting as a bacterial barrier, and 2) provide a scaffold for cellular invasion and capillary growth. In time, the matrix would be remodeled; rebuilding the damaged site while simultaneously degrading the collagen-GAG matrix.



**Fig. 5** An Integra Bi-Layer Matrix was utilized to control the vapor loss of the wound, act as a bacterial barrier, and provide a scaffold for cellular invasion and capillary growth

The proximal leg incision was then re-approximated with 3-0 Vicryl and skin staples. The Integra graft was then covered with a wound VAC and set at 70 mmHg and continuous flow. Wound VAC was applied for one month to ascertain the viability of the muscle flap and readiness for partial split thickness skin graft (**Fig. 6**).

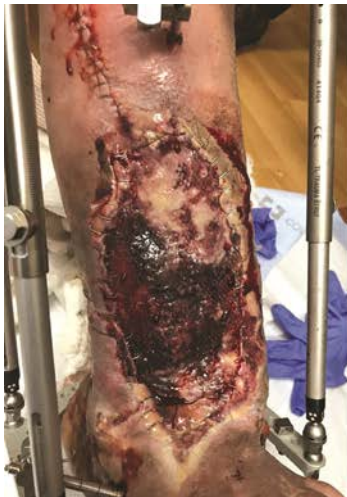

**Fig. 6** A wound VAC was utilized and set at 70 mmHg and continuous flow. Wound VAC was applied for one month to ascertain the viability of the muscle flap and readiness for partial split thickness skin graft

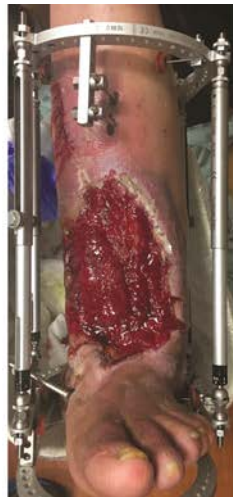Post-operative wound care commenced for one month, preparing the surgical site for a partial thickness skin graft. At the one week post-operative follow-up visit, it was noted that a hematoma developed deep to the Integra Bi-Layer Matrix. This layer was then fenestrated, which yielded serosanguinous drainage. The wound VAC was then reapplied to the surgical site and dressed with sterile dressings (**Fig. 7**). At the three week post-operative follow-up, the surgical site was ready for partial thickness skin graft (**Fig. 8**).

A month after the initial soleus muscle flap, a 0.018 inch partial thickness skin graft was harvested from the medial thigh and applied to the wound defect (Fig. 9) and wound VAC was re-applied. Vessel loops served as a skin buffer for retention stitches. Wound VAC and local wound care were continued into post-operative visits (Fig. 10). Serial radiographs of the leg were also obtained (Fig. 11). Patient demonstrated progressive closure

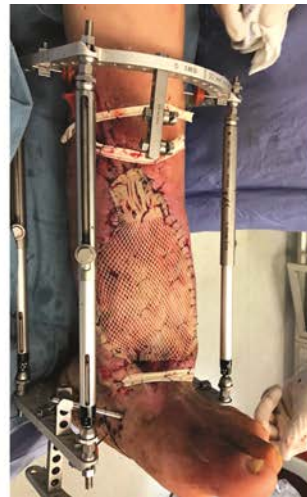and healing of the wound (Fig. 12). Healing was achieved in three months, which at this time, the external fixation device was removed and a compression dressing with posterior splint was applied (Fig. 13). Four months status post procedure, the patient was ambulating in a patella tendon bearing orthosis. A noticeable soleus muscle bulge was still present (Fig. 14). This bulge atrophied in time as shown by five month operative pictures (Fig. 15).



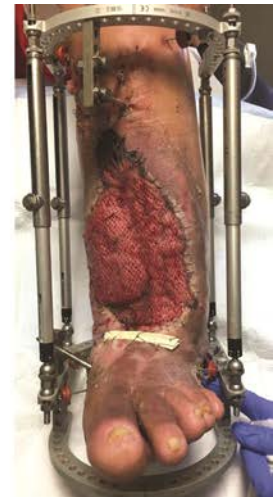**Fig. 7** One week post-operative follow-up visit. A hematoma developed under the Integra Bi-Layer Matrix. This graft was fenestrated and wound VAC was re-applied



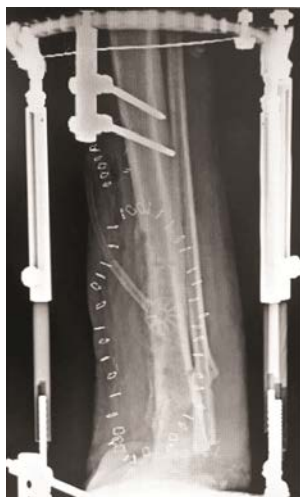**Fig. 8** Three week post-operative follow-up visit. Donor site is granular and ready for partial thickness skin graft



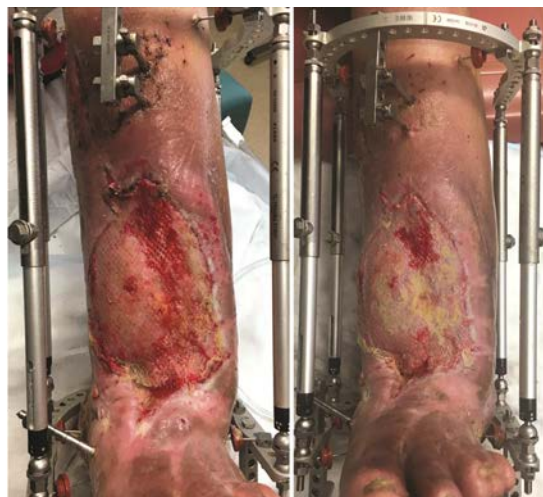**Fig. 9** Intra-operative photo utilizing a 0.018 inch partial thickness skin graft from the medial thigh. Vessel loops served as a skin buffer from retention stitches



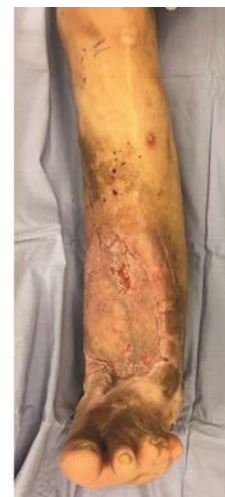**Fig. 10** Post-operative follow-up at one week status post partial thickness skin graft application



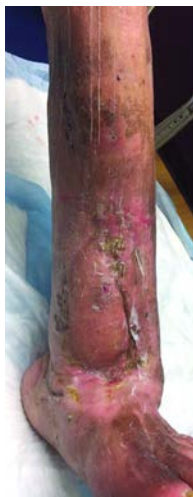**Fig. 11** Post-operative radiograph film status post partial thickness skin graft. The Orthofix TrueLok Trauma Frame was formed with two half pins and wire at the tibial support and one half pin and two wires at the midfoot. Corresponding fixation pins were inserted into the leg and foot and tension appropriately



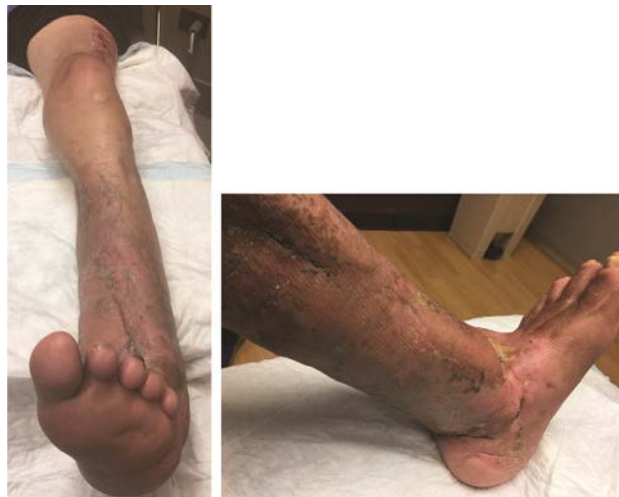**Fig. 12** Two and three weeks status post partial skin graft application



**Fig. 13** Three months status post original soleus muscle flap, the external fixation device was removed



**Fig. 14** Patient four months status post soleus muscle flap. Patient ambulating in patella tendon bearing orthosis



**Fig. 15** Five months status post soleus muscle flap. Cosmesis has improved due to soleus muscle flap atrophy

## DISCUSSION

The ankle poses a difficult region for coverage of soft tissue defects. Often, these wounds exist in either vascular compromised or medically frail patients. Local rotation flaps with free tissue transfer to cover difficult ankle wounds are an alternative to amputation [1–3]. However, these techniques require considerable microsurgical skills and in at-risk patients, considerable operative time and donor site morbidity. Thus in at risk patients, an alternative technique should be sought, such as the soleus muscle flap.

In general, a flap should also be technically easy to harvest, be reliable, and have a high success rate with minimal donor site morbidity. The soleus muscle flap fits these criteria and has shown good results in covering defects in the distal leg. This transposition allows for primary healing of wounds, reliable soft-tissue coverage, and good cosmetic outcome as the initial muscle bulk atrophies and decompresses with time. The soleus muscle flap can be used for open fractures, chronic wounds, and anterior ankle wounds such as those with complications in total ankle replacements. The technique is a reliable local option for soft-tissue coverage that can offer a good outcome and minimal morbidity.

In this case report, we demonstrate the use of the soleus muscle flap for wound coverage. This soleus muscle itself is classified by Mathes as type II: having dominant vascular pedicles plus minor pedicles.

In addition to the soleus, other muscles in this group with similar vascular anatomy include the abductor digiti minimi, abductor hallucis, biceps femoris, flexor digitorum brevis, gracilis, peroneus longus, peroneus brevis, platysma, semitendinosus, sternocleidomastoid, temporalis, trapezius, and the vastus lateralis (**Table 1**).

Though technically easy, the surgeon must be meticulous in dissection to prevent damage to the vascular perforators of the muscle flap. In order to optimize success of

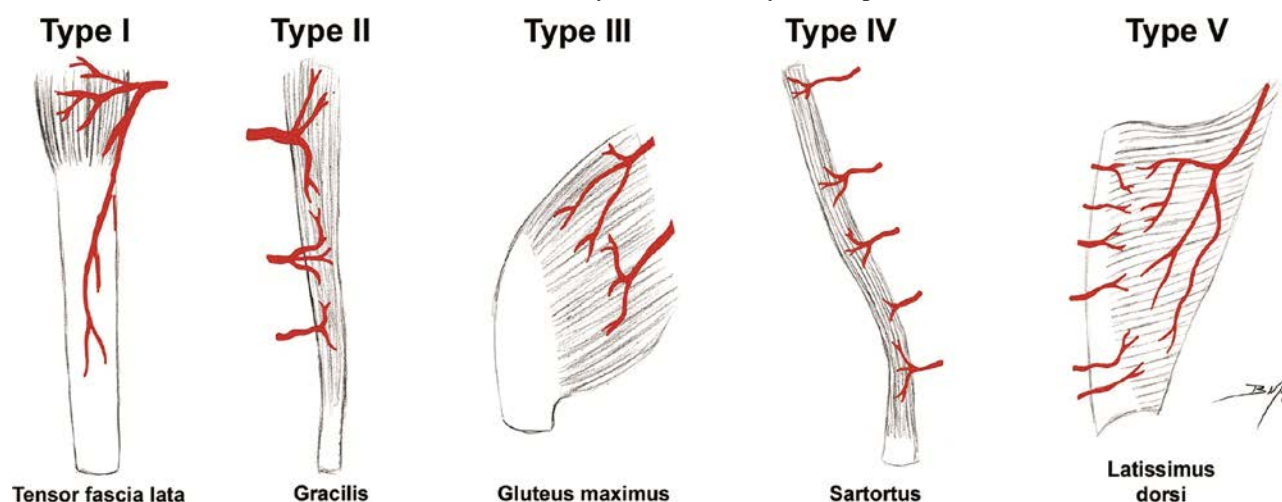
this muscle flap, the following were used: 1) an external fixation device to prevent traction post operatively; 2) an Integra Bi-Layer Matrix to control the vapor loss of the wound, act as a bacterial barrier, and provide a scaffold for cellular invasion and capillary growth; 3) a wound VAC to draw out fluid from the wound and increases blood flow to the area, 4) a 0.018 inch partial thickness skin graft, providing balance between an intermediate and thick graft [17]. The patient must be a good surgical candidate and compliant to post-operative instructions. If qualified, limb salvage can be an alternative to amputation.

Since Mathes and Nahai's 1981 paper on vascular anatomy of muscles, many muscle transpositions and flaps have been utilized for plastic and reconstructive surgery. More recently in a descriptive study by Ata-ul-Haq, ten patients with middle third tibial wound defects had a hemisoleus muscle flap performed. All the flaps survived with primary healing of the wound except one patient who developed wound infection which settled after wound drainage and irrigation [11]. In a prospective study by Ahmad et al., forty patients aged 15–65, had middle and lower third defects with exposed bone present in the leg. In all cases, a proximally-based hemisoleus flap was used. All the flaps survived except five which developed partial skin graft loss, and one where complete flap loss was observed [12].

In conclusion, the soleus muscle flap provides a viable option for ankle wound coverage, especially in medically frail patients. Due to a high degree of versatility, reliability, minimal donor site morbidity, less operating time, low cost and good functional gain; this procedure is highly suitable for the treatment of complex middle and lower leg defects. It should be considered in the reconstruction of soft tissue defects about the ankle, especially when the surgeon has exhausted all other conservative and surgical options.

Table 1

Patterns of muscle vascular anatomy as described by Dr. Stephen Mathes [15, 18]



## REFERENCES

- Rodriguez Collazo E.R., Rathbone C.R., Barnes B.R. A Retrospective Look at Integrating a Novel Regenerative Medicine Approach in Plastic Limb Reconstruction. *Plast. Reconstr. Surg. Glob. Open*, 2017, vol. 5, no. 1, pp. e1214. DOI: 10.1097/GOX.0000000000001214.
- Rodriguez Collazo E.R., Khan A.A., Khan H.A. An algorithmic approach towards the orthoplastic management of osseous and soft tissue defects in post-traumatic distal tibial fractures. *J. Orthop. Trauma Surg. Rel. Res.*, 2017, vol. 12, no. 2, pp. 57-61.
- Rodriguez Collazo E.R., Bibbo C., Mechell R.J., Arendt A. The reverse peroneus brevis muscle flap for ankle wound coverage. *J. Foot Ankle Surg.*, 2013, vol. 52, no. 4, pp. 543-546. DOI: 10.1053/j.jfas.2013.02.021.
- Lachica R.D. Evidence-Based Medicine: Management of Acute Lower Extremity Trauma. *Plast. Reconstr. Surg.*, 2017, vol. 139, no. 1, pp. 287e-301e. DOI: 10.1097/PRS.0000000000002860.
- Karanas Y.L., Nigriny J., Chang J. The timing of microsurgical reconstruction in lower extremity trauma. *Microsurgery*, 2008, vol. 28, no. 8, pp. 632-634. DOI: 10.1002/micr.20551.
- Arnold P.G., Yugueros P., Hanssen A.D. Muscle flaps in osteomyelitis of the lower extremity: a 20-year account. *Plast. Reconstr. Surg.*, 1999, vol. 104, no. 1, pp. 107-110.
- Hughes L.A., Mahoney J.L. Anatomic basis of local muscle flaps in the distal third of leg. *Plast. Reconstr. Surg.*, 1993, vol. 92, no. 6, pp. 1144-1154.
- Yunus A., Yusuf A., Chen G. Repair of soft tissue defect by reverse soleus muscle flap after Pilon fracture fixation. *Zhongguo Xiu Fu Chong Jian Wai Ke Za Zhi*, 2007, vol. 21, no. 9, pp. 925-927.
- Pu L.L. Soft-tissue coverage of an open tibial wound in the junction of the middle and distal thirds of the leg with the medial hemisoleus muscle flap. *Ann. Plast. Surg.*, 2006, vol. 56, no. 6, pp. 639-643. DOI: 10.1097/01.sap.0000205818.82084.cf.
- Pu L.L. Soft-tissue coverage of an extensive mid-tibial wound with the combined medial gastrocnemius and medial hemisoleus muscle flaps: the role of local muscle flaps revisited. *J. Plast. Reconstr. Aesthet. Surg.*, 2010, vol. 63, no. 8, pp. e605-e610. DOI: 10.1016/j.bjps.2010.05.003.
- Ata-ul-Haq, Tarar M.N., Malik F.S., Khalid K., Riaz A., Mehrose M.Y., Khan H. Hemisoleus muscle flap, a better option for coverage of open fractures involving middle third of tibia. *J. Ayub. Med. Coll. Abbottabad*, 2009, vol. 21, no. 4, pp. 154-158.
- Beck J.B., Stile F., Lineaweaver W. Reconsidering the soleus muscle flap for coverage of wounds of the distal third of the leg. *Ann. Plast. Surg.*, 2003, vol. 50, no. 6, pp. 631-635. DOI: 10.1097/01.SAP.0000054185.22788.0F.
- Wright J.K., Watkins R.P. Use of the soleus muscle flap to cover part of the distal tibia. *Plast. Reconstr. Surg.*, 1981, vol. 68, no. 6, pp. 957-958.
- Ahmad I., Akhtar S., Rashidi E., Khurram M.F. Hemisoleus muscle flap in the reconstruction of exposed bones in the lower limb. *J. Wound Care*, 2013, vol. 22, no. 11, pp. 635, 638-640, 642. DOI: 10.12968/jowc.2013.22.11.635.
- Mathes S.J., Nahai F. Classification of the vascular anatomy of muscles: experimental and clinical correlation. *Plast. Reconstr. Surg.*, 1981, vol. 67, no. 2, pp. 177-187.
- Ovaska M.T., Madanat R., Tukiainen E., Pulliainen L., Sintonen H., Mäkinen T.J. Flap reconstruction for soft-tissue defects with exposed hardware following deep infection after internal fixation of ankle fractures. *Injury*, 2014, vol. 45, no. 12, pp. 2029-2034. DOI: 10.1016/j.injury.2014.10.006.
- Seyhan T. Split-Thickness Skin Grafts. Ch. 1. In: Spear M., ed. *Skin Grafts - Indications, Applications and Current Research*. InTech, 2011, 384 p. DOI: 10.5772/892
- Chrysopoulou M.T. *Tissue Flap Classification*. De la Torre J., chief ed. MedScape, 2017. Available at: [emedicine.medscape.com/article/1284474-overview](http://emedicine.medscape.com/article/1284474-overview).

Received: 22.01.2018

## Information about the authors:

- Edgardo Rodriguez-Collazo, DPM, Presence Saint Joseph Hospital – Chicago, Chicago IL, USA, Director Chicago Foot & Ankle Deformity Correction Center, Ilizarov Correction & Microsurgical Limb Reconstruction, Dept of Surgery
- Jonathan Huey, DPM, Presence Saint Joseph Hospital – Chicago, Chicago IL, USA, Podiatric Surgery Resident, PGY-2